ELSEVIER

Seminars in
NUCLEAR
MEDICINE

Current Status of Prostate-Specific Membrane Antigen Targeting in Nuclear Medicine: Clinical Translation of Chelator Containing Prostate-Specific Membrane Antigen Ligands Into Diagnostics and Therapy for Prostate Cancer

Clemens Kratochwil, MD,[*] Ali Afshar-Oromieh, MD,[*,†] Klaus Kopka, PhD,[‡] Uwe Haberkorn, MD,[*,†] and Frederik L. Giesel, MD[*]

The prostate-specific membrane antigen (PSMA) is expressed by approximately 90% of prostate carcinomas. The expression correlates with unfavorable prognostic factors, such as a high Gleason score, infiltrative growth, metastasis, and hormone-independence. The high specificity, especially in the undifferentiated stage, makes it an excellent target for diagnosis and therapy. Therefore, antibodies and small molecule inhibitors have been developed for imaging and therapy. In 2011 PSMA-11, a ligand that consists of the Glu-urea-motif and the chelator HBED-CC, which can be exclusively radiolabeled with ^{68}Ga for PET imaging, presented the clinical breakthrough for prostate cancer diagnostics. In two large diagnostic studies ($n = 319$ and $n = 248$) PET/CT with PSMA-11 successfully localized the recurrent tumor in approximately 90% of patients with biochemical relapse. Integrating PSMA-PET/CT into the planning phase of radiotherapy, the treatment concept is changed in 30%-50% of the patients. The combination of the Glu-urea-motif with DOTA, which can be labeled with several diagnostic and therapeutic radionuclides, opened new avenues for therapeutic usage of the small-molecule PSMA ligands. In the beginning of 2016, there are four confirmative reports ($n = 19$, $n = 24$, $n = 30$, and $n = 56$) from four different centers reporting a PSA response in approximately 70% of patients treated with ^{177}Lu-labeled PSMA ligands. In conclusion, the data available up to now indicate a widespread use of PSMA ligands for diagnostic applications with respect to staging, detection of recurrence, or metastases in patients with rising tumor markers and for therapy in case of failure of guideline-compliant treatment.

Semin Nucl Med 46:405-418 © 2016 Elsevier Inc. All rights reserved.

*Department of Nuclear Medicine, University Hospital Heidelberg, Heidelberg, Germany.
†Clinical Cooperation Unit Nuclear Medicine (E060), German Cancer Research Center (dkfz), Heidelberg, Germany.
‡Division of Radiopharmaceutical Chemistry, German Cancer Research Center (dkfz), Heidelberg, Germany.
Address reprint requests to Uwe Haberkorn, MD, Department of Nuclear Medicine, University Hospital Heidelberg, INF 400, Heidelberg 69120, Germany. E-mail: uwe.haberkorn@med.uni-heidelberg.de

http://dx.doi.org/10.1053/j.semnuclmed.2016.04.004
0001-2998/© 2016 Elsevier Inc. All rights reserved.

Background About Prostate Cancer: Epidemiology, Current Standard Procedures and the Unsolved Clinical Demand for Improvement

Today, with 240,000 diagnosed men in the United States[1] and 420,000 in Europe,[2] prostate cancer (PC) is one of the most common malignancies in the world. Despite the good prognosis of indolent PC, even the limited number of aggressive tumors translates into a high lethality, which also presents a tremendous increase over time. In 1990, only 156,000 men died of PC; but in 2010, the number had already increased to 256,000 deaths worldwide.[3] Screening and initial diagnosis is traditionally based on serum tests for prostate-specific antigen (PSA) and sonography-guided needle biopsy. However, during the last decade noninvasive multiparametric MRI presented some improvement helping to decide on the indication, type, and localization of a prostate biopsy for cancer diagnosis.[4] The treatment for localized PC is tailored into active surveillance, radical prostatectomy, radiotherapy, or other focal therapy, depending on tumor characteristics, Gleason score, PSA value, and the patient's life expectancy. Treatment with a curative intent is not used in all patients with localized PC, because many cases of well-to-moderately differentiated PCs have a very indolent course and are not lethal. In contrast to other solid tumors, active surveillance can be the strategy of choice even for potentially curable patients. Thus, for low-risk patients, conventional imaging still contributes less to the staging procedures before further treatment stratification.[5] The clinical challenge for diagnostic imaging of primary tumors presents the differentiation between indolent forms of PC and aggressive ones. The latter contribute approximately 15% of the prostate tumors.[6] The oncologic standard tracer FDG is not widely used in PC as primary tumors as well as lymph node metastases present a variable glucose dependency, and detection rates for well-to-moderate differentiated tumors have been found low, that is, in the dimension of 30%.[7,8] Attempts to use amino acid tracers resulted into similar variable success with significant limitations to either sensitivity (eg, ^{11}C-methionine) or specificity (eg, ^{18}F-FACBC).[5,9] Targeting lipid metabolism with ^{11}C-acetate presented more promising data[5]; but because of the short half-life of ^{11}C (20 minutes), this tracer is not suitable for clinical routine. ^{11}C-choline, a tracer representing membrane synthesis, demonstrated similar characteristics than ^{11}C-acetate but could also be fluorinated to receive ^{18}F-fluoro-ethyl-choline (FECh) or fluoromethylcholine (FMC). The longer half-life of ^{18}F (110 minutes) was advantageous for clinical routine. Recently, the clinical value of choline-PET/CT was summarized in a meta-analysis.[10] Although the pooled detection rate was 62%, the rate for the subgroup reporting dedicated rates for nodal disease and bone metastases were only 36% and 25%, respectively. Thus, the limited detection rate or the sensitivity of PC imaging in the pre-PSMA era were somehow unsatisfying, leading to further research developing new diagnostic targets.

The Prostate-Specific Membrane Antigen Represents an Ideal Target Structure

The prostate-specific membrane antigen (PSMA), also known as folate hydrolase I or glutamate carboxypeptidase II, shows several biological features making it an ideal target structure for ligand development for nuclear medicine procedures. In particular, PSMA is a type II transmembrane protein with glutamate-carboxypeptidase activity and thus, based on known substrates it is possible to develop small-molecule PSMA-targeted radiopharmaceuticals. In contrast to antibodies, small molecules show a fast blood clearance leading to a low background activity. Furthermore, after the binding of the ligand to its membrane-anchored target, internalization occurs via clathrin-coated pits and endocytosis, resulting in an effective transportation of the bound molecule into the cells ending up in the late endosomes.[11] This leads to enhanced tumor uptake and retention, and it results in high-image quality for diagnostic procedures and a high local dose for therapeutic applications. As already mentioned, PSMA is a cell-surface protein that shows a significant overexpression on most prostatic cancer cells, especially in advanced-stage prostate carcinomas and no expression or only a low expression in normal human tissues.[12,13] Several studies revealed an association of PSMA with stage and grade, showing increasing PSMA levels with higher stages and grading of the tumor.[13-15]

Owing to the fact that PSMA is expressed in most prostate carcinomas, many attempts dealt with the development of potential binders to this enzyme. Besides antibodies,[16,17] targeted nanoparticles[18,19] and aptamer conjugates,[20,21] other strategies used small-molecule inhibitors developed by industry for their modification to radiopharmaceuticals.[22-24] The first antibody used was the monoclonal antibody 7E11-C5 that was approved by the Food and Drug Administartion as ProstaScint.[25] However, 7E11-C5 was found to bind to the intracellular part of PSMA, preventing its binding to intact cells and therefore, leading to very-low detection rates.[26] In contrast, the second generation antibody J591 binds to the extracellular domain of PSMA and has been used in clinical trials showing improved targeting of PC.[27]

Although antibodies offer potential for tumor targeting, their effectiveness as diagnostic radiopharmaceuticals is limited by a long biological half-life and poor tumor penetrability. Approaches that may overcome these limitations are combining antibodies with the longer-lived PET radionuclides ^{89}Zr and ^{64}Cu[28] or using single-chain fragments or the anti-PSMA minibody ^{89}Zr-Df-IAB2M as smaller variants of the humanized J591.

Studies on the development of small-molecule inhibitors mimicking the endogenous substrate N-acetyl-L-aspartyl-L-glutamate (NAAG), which is cleaved by N-acetylated alpha-linked acidic dipeptidase NAALADase or glutamate carboxypeptidase II, identified various candidates.[29,30] The insight into the structural and functional[31,32] homology between NAALADase and PSMA paved the way to the use of these small molecules in targeted treatment and imaging of PC.

Following this line, several small-molecule PSMA inhibitors labeled with a variety of radionuclides were developed based on the structural motifs of various NAALADase inhibitors.[33-41] In 2008, the first diagnostic high-affinity small-molecule inhibitors of PSMA, ^{123}I-MIP-1072 and ^{123}I-MIP-1095 were introduced into the clinic. In men with metastatic PC, SPECT/CT using these molecules demonstrated the ability to rapidly detect lesions in soft tissue, bone, and the prostate gland as early as 1-4 hours after injection.[38]

PSMA-PET/CT for Primary Staging

To correctly diagnose the primary tumor of PC, can be challenging. Approximately 70% of all PCs are located in the peripheral zone, and there is no obstacle to identify and biopsy most of these tumors with transrectal ultrasonography. However, some tumors are located in the anterior peripheral zone ventral of the urethra and also 20% of tumors are located in the central and 10% tumors in the transition zone. This particular subgroup of primary PC is challenging to be localized and often need repeated biopsies until the final diagnoses can be done.[42] In addition, approximately 85% of PCs are multifocal.[43] As a consequence, Gleason score derived from biopsy and succeeding prostatectomy only matched in 69% of the patients evaluated in a comparative trial.[44] As active surveillance becomes more and more important in elderly populations, the effect of risk stratification for patient tailoring, which is largely based on the Gleason score increases the clinical effect to find the dominant intraprostatic lesion. Choline-PET had high detection rates for well-to-moderate differentiated PC but sensitivity decreases with dedifferentiation.[10] In contrast, FDG-PET was only found valuable to identify highly aggressive tumors but presents false-negative in low-and-intermediate Gleason scores.[8] Thus, this clinical need is still unsolved. The literature for PSMA-PET/CT regarding initial PC diagnosis is still rare. In a small study, presurgery PSMA-PET/CT was compared to extensive histologic workup of 112 segments evaluated after six prostatectomies. Despite the physiological uptake in normal prostate tissue, which causes some background accumulation, true positive tumors presented with significant higher standardized uptake values (SUVs) resulting in positive and negative predictive values of 96% and 85%, respectively. The SUVs of ^{68}Ga-PSMA-11 PET/CT correlated also weakly with Gleason score, but due to limited patient number no testing for significance was reasonable.[45] Another group compared PSMA-PET/CT with multiparametric MRI (Fig. 1) in a blind read using the PI-RADS standard reporting schema.[46] If MRI was considered as reference, PSMA-PET/CT presented 90% concordant findings, whereas 97% of lesions detected by PSMA-PET/CT presented a concordant finding in MRI. In a clinical phase-2 trial, the ^{99m}Tc-labeled PSMA ligand MIP-1404 presented sensitivity and specificity of 94% and 100%, respectively, for detecting primary PC in a preselected high-risk population[47] and now its clinical effect (in consequence, patients are tailored to active surveillance vs radical prostatectomy) is evaluated in a prospective phase-3 clinical trial (NCT02615067). The PSMA-targeted imaging thus seems highly promising to improve imaging-guided biopsy by reducing false-negative biopsies and guiding the needle to the lesion with the highest Gleason score, bringing minimal-invasive needle biopsy closer to the level of full prostate histology, strengthening its reliability for patient stratification.

Imaging-Guided Radiotherapy and Surgery

A second challenge in the patient management is the decision between primary radiotherapy and radical prostatectomy either with or without extended pelvic lymphadenectomy or radiation of the lymphatic drainage. Several classification criteria have been proposed to optimize patient management, for example, the D'Amico classification that is based on the PSA level, Gleason score, and T staging.[48] In addition, formulae based on epidemiologic data have been published to pretherapeutically estimate the risk for nodal-positive disease.[49,50] There are some controversies about the best risk-stratification system as well as about deriving the correct clinical consequence. If the risk for N+ exceeds >20%, it is common to include the pelvic lymph drainage into the radiation volume. However, this concept translates into undertreatment of up to 20% low-risk patients and overtreatment in up to 80% of high-risk patients, making more targeted approaches desirable. In a recent publication, ^{68}Ga-PSMA-11 PET/CT as well as conventional imaging-staging procedures (including bone scan, CT, and MRI) were performed with 57 patients scheduled to primary radiotherapy. In 50.8% of the cases, therapy was changed (Fig. 2).[51,52] These data could be confirmed by a different group that found an overall change in decision-making in 53.7% of their 44 patients.[53] In the setting of salvage radiation treatment, a third group found a major management change in 29% of patients after enhancing conventional staging with PSMA-PET/CT. In 9% of the patients, they found metastatic lesions outside the prostatic fossa and pelvic lymph nodes, that is, a change from cN1-cM1.[54]

With regard to surgery, the nomenclature for limited, standard, and extended pelvic lymph node dissection (PLND) lacks standardization that makes it difficult to compare different reports. Although limited PLND is considered a diagnostic procedure that can be performed during prostatectomy without additional time consumption and low complications, the standard and extended PLND were found to correlate with patient prognoses according to the large SEER dataset.[54] However, only 25% of the lymph node metastases are in the area of standard PLND predominantly around the internal iliac artery.[54] The extended PLND (including the area between the ureters) is time consuming and can cause additional and more severe complications, for example, injury to the presacral plexus. The use of sentinel lymph node (SLN) marker techniques revealed that several patients present with untypical lymphatic drainage, for example, pararectal to the mesenteric or into inguinal lymph nodes; these regions are even outside the extended PLND area.[55] Nevertheless, lymph node metastases to the SLN region only were reported in only 41% of

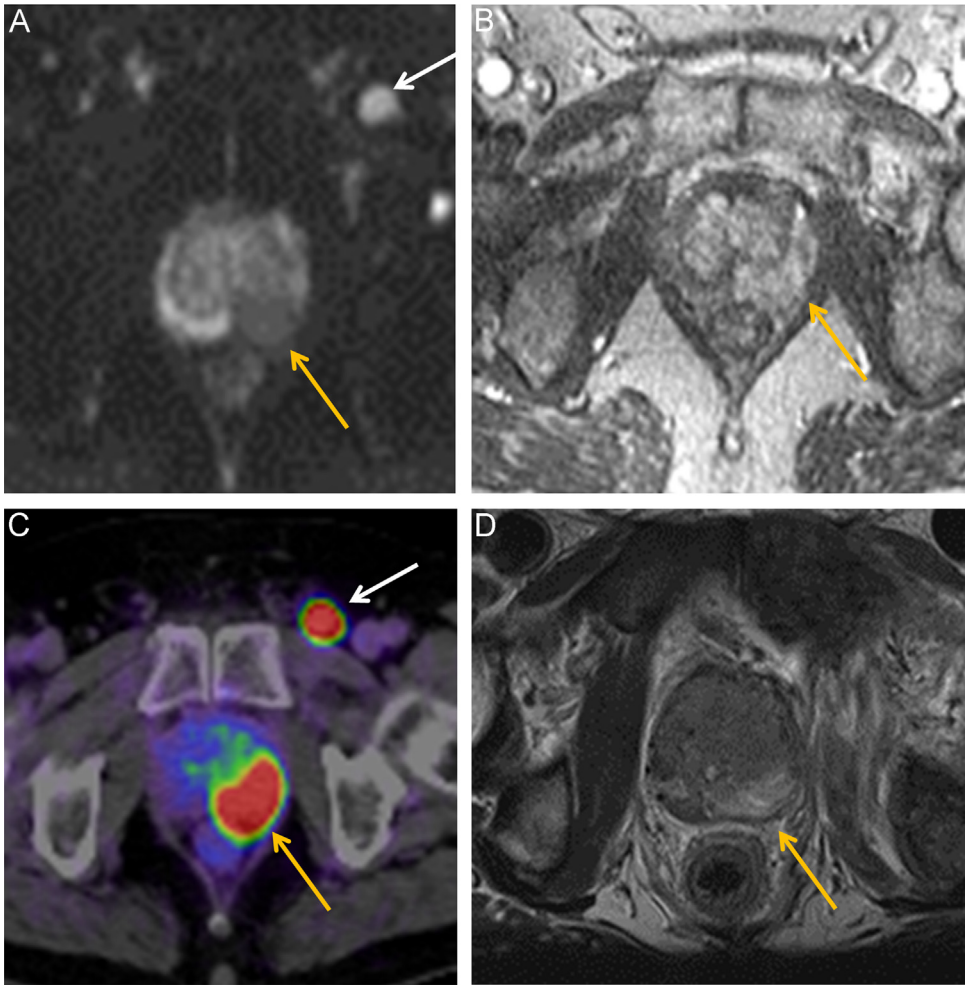

Figure 1 A 61-year-old patient with a biopsy-proven prostate cancer in the left peripheral zone, presented in multiparametric MRI with diffusion restriction in DWI (A), contrast media uptake in ceT1w (B), and hyperintensive in T2w (D). Identical location and a near-total correlation of tumor extend was also demonstrated in ^{68}Ga-PSMA-11 PET/CT (C, red arrow). PSMA-PET also diagnosed a locoregional lymph node metastasis (C, white arrow) that was retrospectively also delineable in DWI (A) and ceT1w (B). ceT1w, contrast-enhanced T1-weighted image; DWI, diffusion-weighted imaging; T2w, T2-weighted image.

patients[56] and therefore the SLN concept is less valuable in prostate than in breast cancer or melanoma. The current radiological standard, the evaluation of short-axis diameter of pelvic lymph nodes, presented relevant limitations,[57] which is unsatisfactory for surgeons to stratify their patients. Thus, new techniques for tailoring patients regarding the extent of lymph node dissection are still of significant clinical interest. A recent study evaluating ^{68}Ga-PSMA-11 PET/CT found 49 positive lymph nodes including 38 (78%) with a diameter of <8 mm (Figs. 3 and 4). The authors came to the conclusion that PSMA-PET/CT is more sensitive than CT-based 3-dimensional volumetric lymph node evaluation in determining the node status of patients with recurrent PC.[58] Despite the low patient number, these results have now been reproduced by a second center[59] and in the setting of primary tumor staging a thorough histologic validation has been performed.[60] However, there is still no proof that improved diagnostics would translate into improved survival. Nevertheless, preliminary results are promising. Extended lymph node dissection, targeted with the use of presurgery PSMA-PET/CT imaging, was performed to 17 oligometastatic patients and PSA stayed less than 0.2 ng/mL for 14 patients despite the fact that no postsurgery therapy was performed in 8 of them.[61] Thus, further studies in the field of presurgery PSMA imaging are needed for a possible inclusion into PC guidelines. An additional idea is to use a hand-held gamma probes for detection of ^{111}In-labeled PSMA ligands in dedicated lesions during surgery. Currently, only a case report for combining presurgery ^{68}Ga-PSMA-11 PET/CT and an on-site gamma-probe measurement of ^{111}In-PSMA-I&T is available.[62] However, the preliminary results reported by this group already seem very promising and the lower kidney, spleen, and soft tissue uptake seen 24 hours p.i. with the novel ligand PSMA-617 in comparison with the earlier ligands like PSMA-I&T[62] and PSMA-11 (Fig. 5) might further improve lesion delineation during surgery.

PSMA Imaging of Recurrent PC

The most extensive data about the clinical effect of PSMA-PET/CT are available in the setting of biochemical recurrence (BCR).

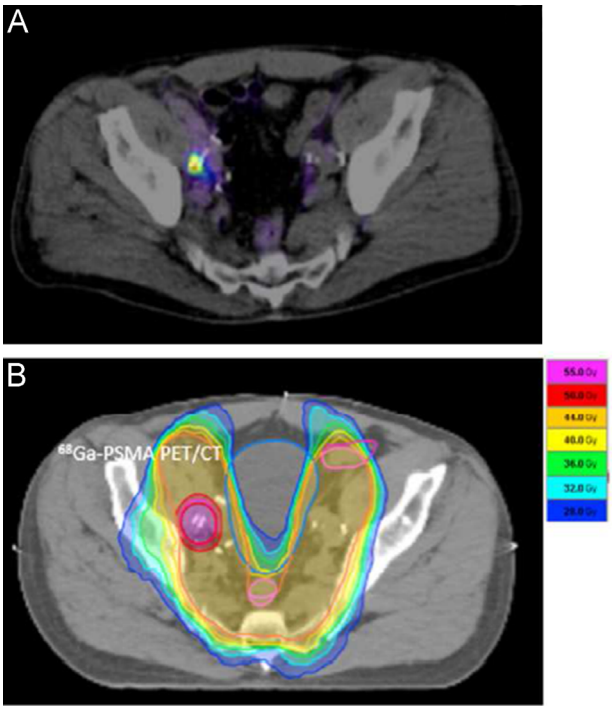

Figure 2 Example of PSA relapse 3 years after prostatectomy and prostate bed irradiation for high-risk prostate cancer. The ^{68}Ga-PSMA-11 PET/CT (A) reveals the iliac lymph node metastases with a SUV_{max} of 9.7 close to postsurgery clip material, which was not found during conventional staging. Radiotherapy corresponding to the presented IMRT plan (B) was done with 26 fractions to the pelvic lymphatic pathways to 46.8 Gy and a simultaneous integrated boost to the lymph node to a dose of 57.2 Gy. The additional treatment intensification to the affected lymph node was achieved without additional toxicity, that is, no lymph edema of the lower extremity occurred. IMRT, intensity-modulated radiation therapy; SUV_{max}, standardized uptake value.

Afshar-Oromieh et al[63] retrospectively analyzed the diagnostic value of ^{68}Ga-PSMA-11 PET/CT in a large cohort of 319 BCR patients with histologic validation in a subgroup of them. A lesion-based analysis demonstrated sensitivity, specificity, negative predictive value, and positive predictive value of 76.6%, 100%, 91.4%, and 100%, respectively; on a patient-based analysis, the sensitivity was 88.1%. Tumor detection was positively associated with PSA level but not with PSA doubling time (PSAdt). Eiber et al[64] analyzed 248 patients and, highly similar to the 88.1% of Afshar-Oromieh et al, found pathologic scans in 89.5%. In a confirmative manner, PSAdt also did not influence the detection rate. The effects of PSA level and PSA kinetics on the detection rate of PSMA-PET/CT have also been investigated in two other studies.[65,66] Ceci et al[65] evaluated ^{68}Ga-PSMA-11 PET/CT in 39 patients with PSA < 2 ng/mL and PSMA-PET/CT was positive in 59% of them, which is in near-total agreement with the study by Afshar-Oromieh who reported a detection rate of 61% in the 90 patients with PSA < 2 ng/mL. However, in contrast to these two studies they found also a strong dependency from PSAdt. Among the patients with PSA < 2 ng/mL, the detection rate was 85% if the PSAdt was <6.5 months, but only 19% if the PSAdt was >6.5 months. The receiver operating characteristic analysis of Ceci et al also suggested a PSA of 0.83 ng/mL as a cutoff to optimize the diagnostic accuracy of PSMA-PET/CT.

Eiber et al,[64] Morigi et al,[66] and an earlier work of Afshar-Oromieh et al[67] also provided subgroup analysis for patients with PSA values between 0.2 and 0.5 ng/mL. The detection rates were in good accordance with 57.9%, 50%, and 50%, respectively. This is an interesting collective. Stringent interpretation of endoscopic ultrasound guidelines define BCR as PSA > 0.2 ng/mL and on the contrary it was considered advantageous for patient's prognosis, if salvage radiotherapy is initiated before PSA exceeds 0.5 ng/mL.[68] Thus, imaging-

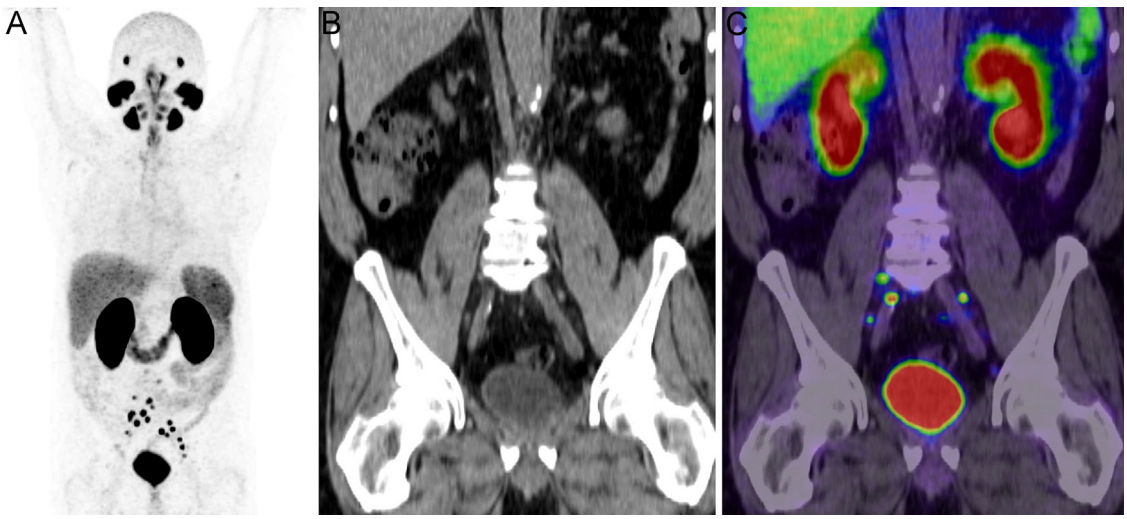

Figure 3 ^{68}Ga-PSMA-11 PET/CT presented with several small lesions in the pelvic region as presented in maximum intensity projection (A). In contrast, the conventional computed tomography visualized only small lymph nodes, all <8 mm short-axis diameter and would not have been considered typical metastases according to morphologic dignity criteria (B). The image fusion (C) illustrates the identity of normal size lymph nodes with intense uptake of the highly specific PSMA tracer.

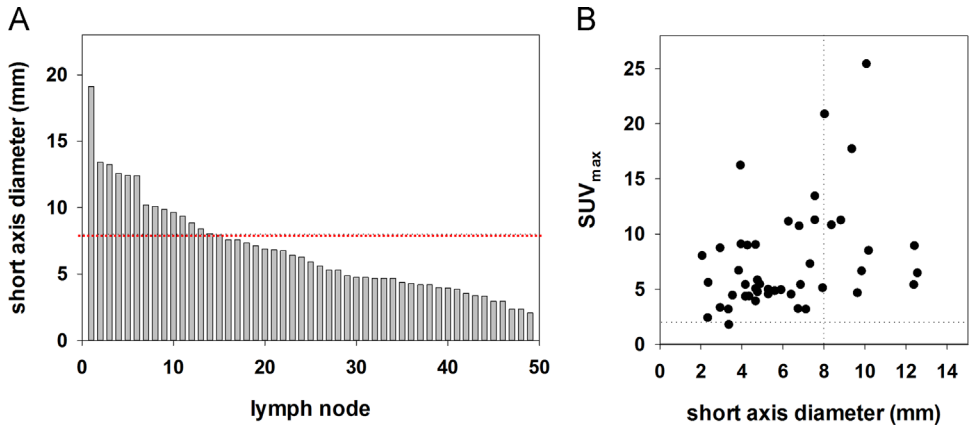

Figure 4 Morphologic distribution of 49 PSMA-positive lymph nodes in terms of their short-axis diameter (A). The relationships between SUV_{max} and the short-axis diameter (B) of the PSMA-positive lymph nodes are also shown (B) and ^{68}Ga-PSMA-11 uptake presented as a criteria for malignancy, independently from lesion diameter. SUV_{max}, standardized uptake value.

guided radiation (eg, focal boost areas) would even be possible in one half of the patients if a PSA of 0.5 ng/mL would serve as a cutoff for the indication toward PSMA-PET/CT in BCR patients.

A natural question is whether ^{68}Ga-PSMA ligands are superior to other PET agents. Regarding the BCR, three authors performed an intraindividual comparison between PSMA-PET/CT and choline-PET/CT.[66-69] In the comparison of

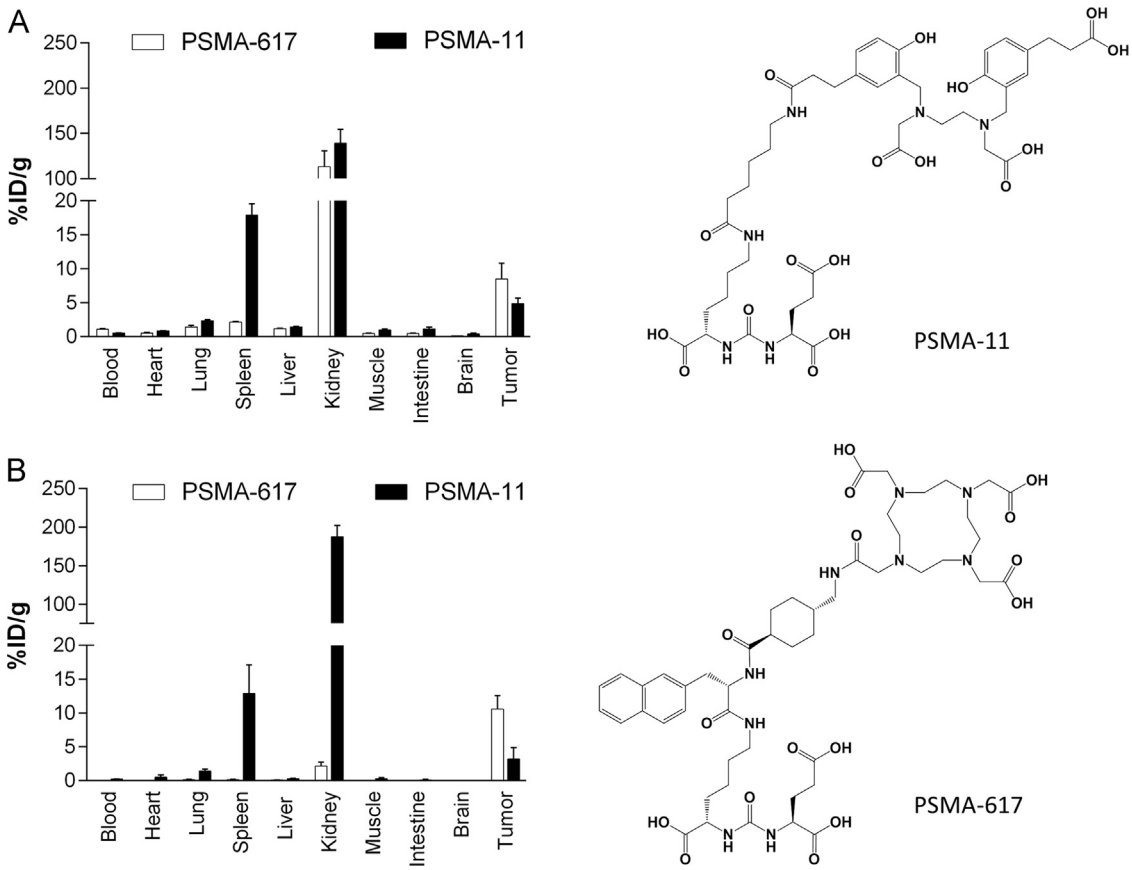

Figure 5 Transformation of diagnostic PSMA-11 into theranostic PSMA-617, presented by organ distribution with %ID/g in LNCaP tumor bearing BALB/c nu/nu mice: At 1-hour p.i. (A) both compounds present similar kidney uptake but at 24-hour p.i. (B), in contrast to PSMA-11, PSMA-617 is widely cleared from the kidneys and presents with an improved tumor to soft tissue (eg, spleen, lung, and muscle) ratio than its antecessors. Simultaneously, improved affinity further increased early tumor uptake; and due to improved internalization (in comparison to PSMA-11), the tumor uptake remains stable until the late time point.

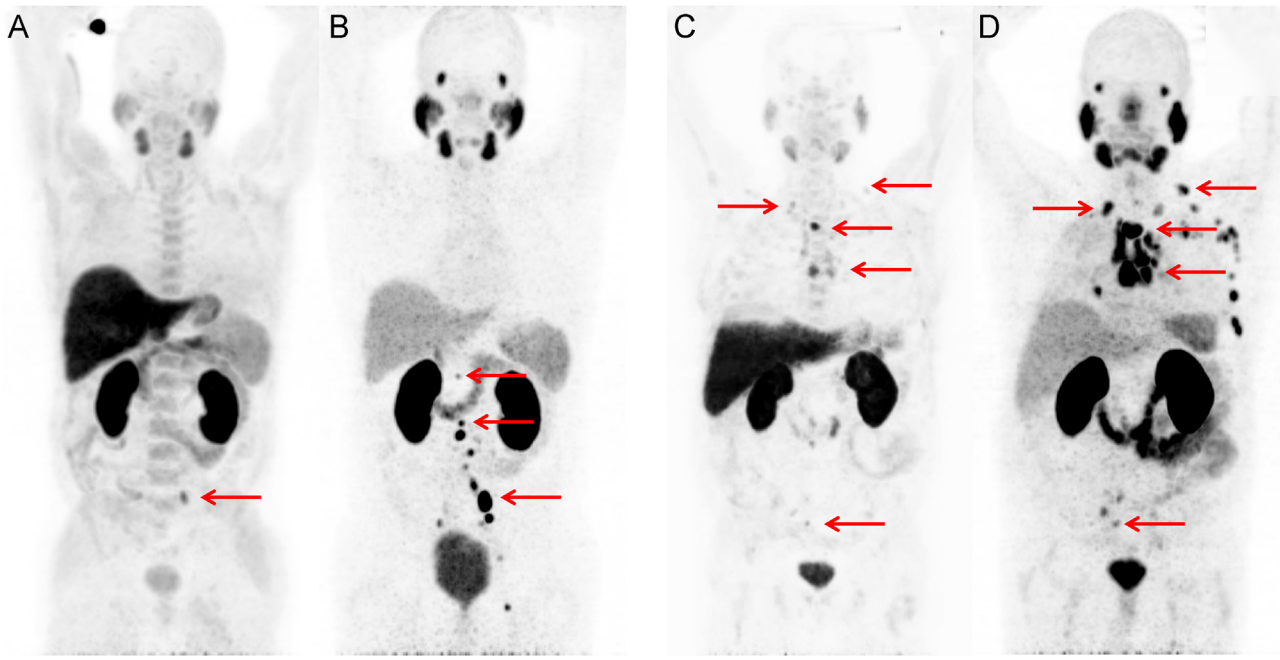

Figure 6 Intraindividual comparison of the former gold standard ^{18}F-fluoromethylcholine (A and C) with the ^{68}Ga-PSMA-11 (B and D) in two patients with recurrent prostate cancer. One patient was staged cN1 in choline-PET due to pelvic lymph node metastases (A), in PSMA-PET additional lesions para-aortal were found defining cM1 stage (B). In another patient, pelvic and thoracic lymph node metastases presented with faint tracer uptake in choline-PET (C), in PSMA-PET higher SUVs and tumor-to-background ratios (D) simplified image interpretation. SUV, standardized uptake value.

Afshar-Oromieh et al, ^{68}Ga-PSMA-11 PET/CT presented a pathologic finding in 32 of 37 BCR patients, choline-PET/CT (^{18}F-FECh) only in 26 of 37 patients; both the SUV_{max} and tumor-to-background ratios were superior for PSMA-PET in most (79% and 95%) lesions. In the comparison of Morigi et al, of 26 patients with positive findings, in 14 patients the findings were positive with PSMA-PET alone, only in one patient the findings were positive in choline-PET (^{18}F-FMC) alone, and the other patients presented with concordant findings. The favorable detection rate of ^{68}Ga-PSMA-11 PET/CT was present for all PSA-stratified subgroups. In 9 of 9 patients with histologic validation, ^{68}Ga-PSMA-11 was true-positive. One patient had histologic validation of a choline-positive but PSMA-negative lymph node and PSMA demonstrated to be true-negative. Bluemel et al had a different approach. This group performed choline-PET/CT first; only if negative (32 of 125 patients) an additional PSMA-PET/CT was performed. The overall detection rate was 86% for the sequential approach and 74% for choline-PET/CT alone. PSMA-PET/CT revealed a positive finding in additional 14 (44%) out of the 32 BCR patients with negative choline-PET/CT (Fig. 6).

Bombesin analogues targeting the gastrin-releasing peptide receptor (GRPr) either labeled with ^{68}Ga[70] or ^{18}F[71] have just recently been introduced for imaging patients with PC. However, one compound failed to detect multiple bone metastases evident on choline-PET,[70] the other only delineated tumors in 3 of 5 patients with primary tumors and found a pathologic lesion in only 2 of 5 patients with BCR.[71] In a pilot study of seven patients PSMA-PET/CT (^{68}Ga-PSMA-11) was directly compared with GRPr-PET/CT (^{68}Ga-RM2) and 44 of 45 lesions were identified with both the compounds, a single lesion was diagnosed with PSMA-PET/CT only. However, in this single case during GRPr-PET the PSA was 6.8 ng/mL that had already increased to 9.2 ng/mL when the PSMA-PET was performed.[72] Therefore, even in the PSMA era, GRPr targeting remains of relevant interest, especially as the two compounds have distinct physiological biodistribution that might be of relevance regarding the dose-limiting organs if the tracers are used during radionuclide therapy. The diagnostic relevance of addressing two different target structures regarding the intra-individual and interindividual tumor heterogeneity needs further evaluation. Recently, a novel bispecific PSMA/GRPr targeting radioligand was evaluated preclinically and demonstrated similar receptor affinities than its respective monomer.[73] However, it should be noted that these bispecific ligands have to be carefully designed and optimized in pharmacokinetics as they may increase the background activity by accumulation in a broader range of normal organs.

PSMA Imaging of Advanced-Stage Metastatic PC

In BCR, early localization of the relapsing tumor may result in additional curative attempts like selective resection or locally boosted radiotherapy, and high sensitivity is the most deserved parameter for a diagnostic tracer. In contrast, in the metastasized stage it is of less clinical effect whether a diagnostic probe

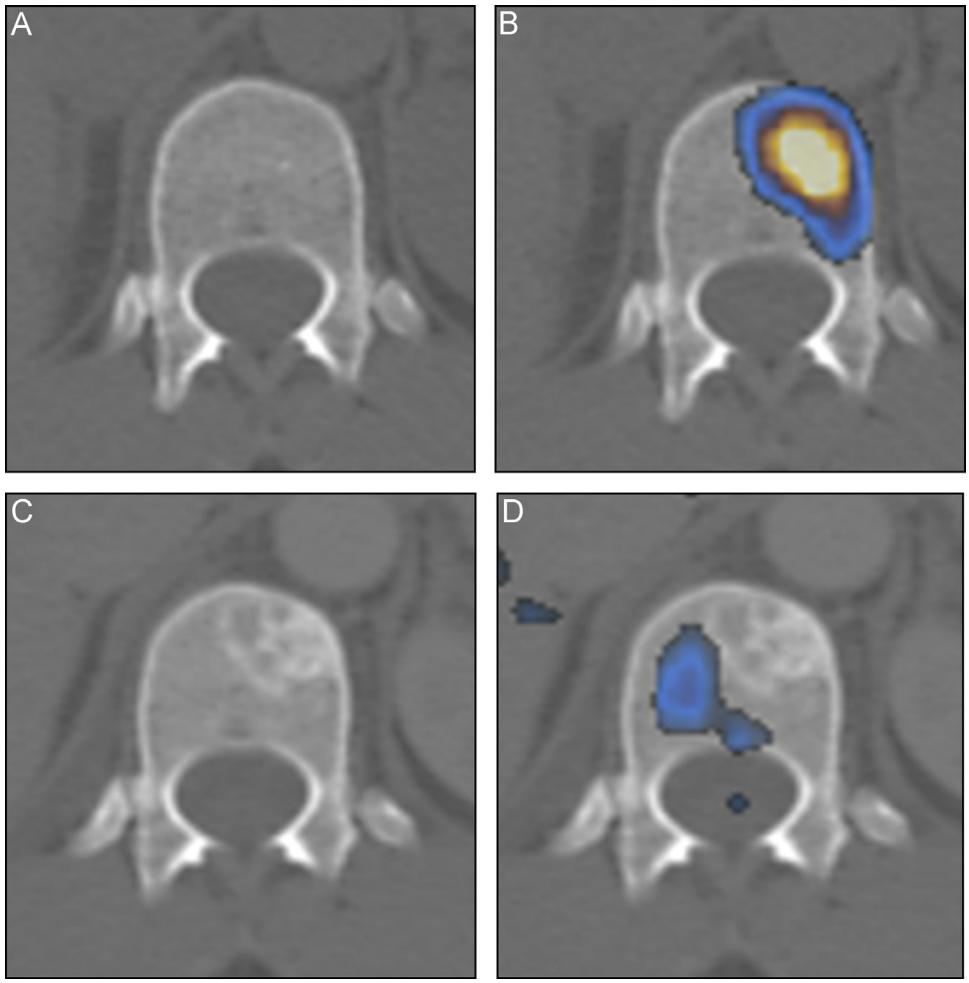

Figure 7 During initial staging (A and B), no bone metastases could be delineated with computed tomography (A), but was demarked by intense, focal-type tracer uptake in PSMA-PET/CT (B). After PSMA-RLT with ^{131}I-MIP1095, the pathologic tracer uptake diminished (D). However, the lesion became sclerotic (C), which most probably should be interpreted as positive treatment response, but could be misinterpreted as a new osteoblastic lesion (pseudoprogression).

can identify, for example, 70, 80, or 90 lesions because systemic drugs are always indicated in this setting. Therefore, conventional bone scan remains the mainstay for follow-up imaging of metastasized castration-resistant PC (mCRPC) in clinical routine, despite a higher sensitivity and specificity of ^{18}F-fluoride PET/CT has already been demonstrated.[74] On the contrary, reaching the metastatic stage brings in new challenges in the management of patients with PC. As all effective treatments are associated with clinical side effects and also "economical toxicities"are of particular interest to either find predictive stratification criteria for a particular treatment or to conduct an early evaluation of response to stop ineffective treatments soon. Regarding the androgen-deprivation therapy, ^{18}F-fluoro-dihydrotestosterone was used to image androgen receptors (ARs) and demonstrated feasible to document the competitive binding of the drug flutamide.[75] However, ^{18}F-fluoro-dihydrotestosterone is a very specific method, whereas androgen-deprivation therapy is normally well tolerated and also quite cheap; therefore, the clinical and economic effect to monitor its effectivity is less interesting than for chemotherapy or the expensive novel drugs. In conventional bone scan or CT, it is possible that previously occult osteolytic lesions become sclerotic after successful treatment and their appearance on the first follow-up examination can be misinterpreted as progression (Fig. 7); this well-known "flare-phenomenon" prohibits early response assessment during the first 12 weeks after changing the treatment regime. However, the "flare phenomenon" is also of clinical significance regarding the PSA serum level, limiting its value for response evaluation in a similar manner.[76] In addition, hormones and taxanes have also been reported to downregulate the secretion of PSA per viable tumor cell, which may account for the significantly higher PSA response rates (45%-50%) relative to measurable response rates (8%-17%) reported in docetaxel trials and makes PSA a less suitable surrogate for response quantification during chemotherapy. In contrast, docetaxel was not found to change the expression of PSMA per tumor cell.[77] A more controversial discussion is needed regarding primary and secondary hormone manipulations. Gene analysis or transcription analysis demonstrated that physiological levels of androgen can

suppress the promoter of the PSMA gene.[78] Preclinical studies found, that initiation of androgen deprivation (ADR) induces an early but temporally upregulation of PSMA expression, whereas in contrast the prolonged ADR leads to a down-regulation of PSMA, followed by a constitutive overexpression of PSMA in resistant tumors.[79-83] Thus, PSMA expression is not independent from AR manipulations and the clinical significance of ongoing ADR, abiraterone, or enzalutamide treatment on targeting PSMA during diagnostic or therapeutic nuclear medicine has still to be elucidated. Actually, only one case report is available reporting sequential PSMA-PET/CT for evaluation of response to ^{223}Ra therapy and described a fulminant flare-up of ^{68}Ga-PSMA-11 accumulation.[84] In conclusion, the clinical effect of PSMA-PET/CT regarding imaging-based response evaluation has not sufficiently been studied, yet.

For patient stratification with regard to PSMA-targeted radioligand therapy (PSMA-RLT), it is consensus that validation of PSMA-positive tumor phenotype either by PSMA-PET/CT or scintigraphy is a precondition to receive therapy (Fig. 8). The currently still unsolved question is whether the tumor uptake 1-4 hours p.i., measurable with ^{68}Ga, ^{18}F, or ^{99m}Tc containing diagnostics can serve as a predictor for treatment response because the maximum tumor uptake of ^{177}Lu-PSMA-617 was not found before 20-44 hours p.i. during dosimetry.[85] Thus, until now no cutoff was proposed on how patients with a visually week tracer uptake might reasonable be tailored for or against PSMA-RLT (Fig. 9A).

PSMA-Targeted Radionuclide Therapy of CRPC

Metastasized PC is challenging to treat. Standard first-line therapy is conducted with luteinizing hormone–releasing hormone (LHRH) analogues and LHRH antagonists to lower the serum testosterone to castration level. Alternatively, antiandrogens such as bicalutamide are used to competitively block ARs. This primary antiandrogen treatment has a mean duration of 2 years, which can be lower in tumors with high Gleason score. Recently, abiraterone was approved, a drug that inhibits androgen synthesis both in testes and also in the adrenal glands and therefore has a similar but stronger mechanism of action as LHRH analogues. Another novel drug is enzalutamide, an antiandrogen with much higher affinity to the AR than its ancestors.[86] After primary and secondary hormone manipulations have failed, the mCRPC presents with an inherent resistance against most conventional chemotherapies, with taxanes being the only exception. However, it has been reported that tubulin targeting with taxanes inhibits AR nuclear translocation.[87] As abiraterone or enzalutamide also interfere with AR signaling, these drugs are somehow competitive in their mechanism of action and cross-resistance may occur, making optimal sequencing of the new drugs challenging.[87] Chemotherapeutics that have been functionalized to target PSMA have been considered an option to overcome treatment-resistance of mCRPC.[88] In contrast, PC is usually radiosensitive. Radiotherapy is a standard treatment for

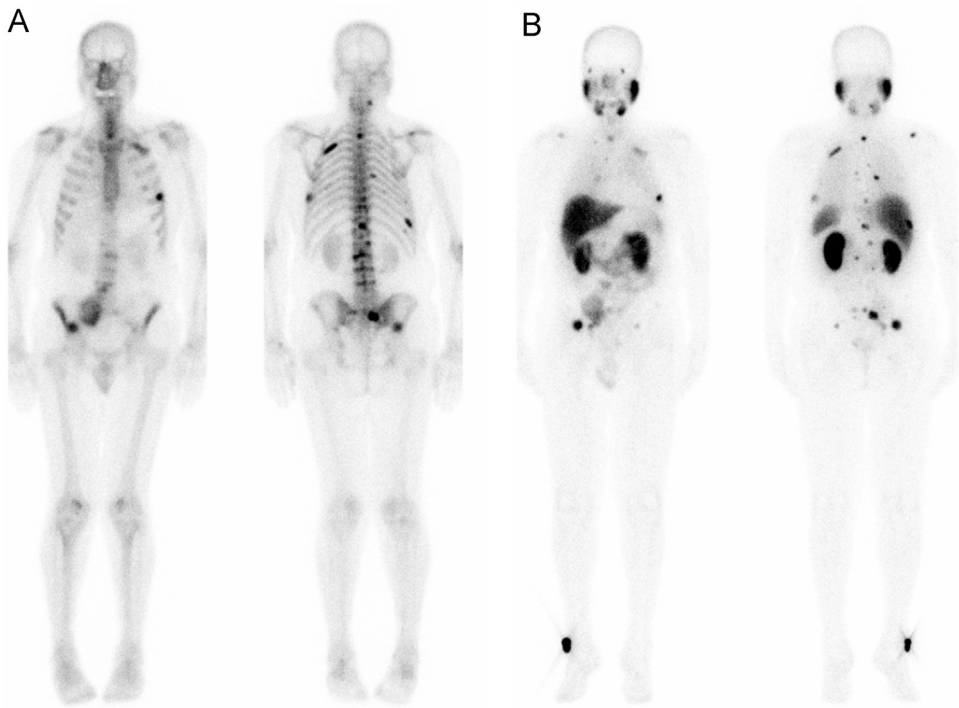

Figure 8 Before PSMA-targeted radioligand therapy, a PSMA-positive tumor phenotype has to be demonstrated either by PSMA-PET/CT or PSMA-scintigraphy. In the presented case, the standard tracer ^{99m}Tc-MDP (planar scans anterior and posterior) served as standard of reference for tumor spread (A). Then PSMA-scintigraphy with ^{99m}Tc-MIP1427 (planar scans anterior and posterior) was done (B) and revealed that all known lesions are targeted.

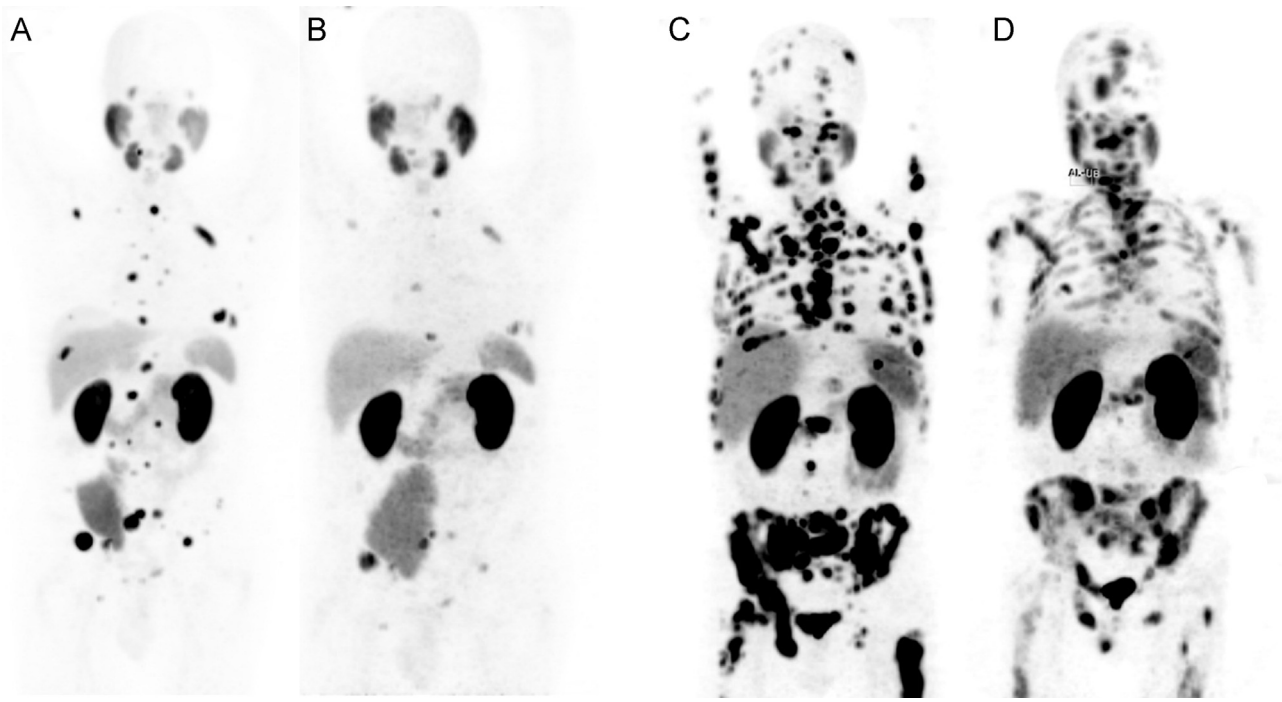

Figure 9 Geometric mean images of planar scans with the PSMA ligand ^{99m}Tc-MIP1427 (same patient like in Figure 8) before (A) and after (B) 3 cycles of ^{177}Lu-PSMA-617 therapy (6 GBq/cycle); corresponding PSA was 61 ng/mL before and 10 ng/mL after treatment. Maximum intensity projections of ^{68}Ga-PSMA-11 PET/CT before (C) and after (D) 3 cycles of ^{177}Lu-PSMA-617 therapy (6 GBq/cycle); corresponding PSA was 459 ng/mL before and 159 ng/mL after treatment.

localized PC and for palliative management of mCRPC, and even radiopharmaceuticals targeting the surrounding bone matrix instead of the tumor itself can improve survival.[89] Therefore, it seemed more promising that PSMA ligands that target tumor cells directly and which are internalized into the cells will be effective in delivering high doses for systemic PSMA-RLT. In contrast to conventional pharmaceuticals, the toxicity and response probability of a radiopharmaceutical predominantly depends on the radiation-absorbed dose to healthy and tumor tissue, respectively. There are well-defined radiation tolerance limits for normal organs. Therefore, empirical dose escalation studies can partially be omitted and dosing of radioactive drugs can be based on dosimetry.

The radiolabeled antibody ^{177}Lu-J591 already demonstrated moderate antitumor effects, but the slow diffusion of antibodies into solid lesions with an uptake of maximum 6-7 days p.i. and hematotoxicity caused by a long circulation time in blood (red marrow dose = 0.3 Gy/GBq) were limitations.[90] Owing to faster kinetics, the PSMA-targeted small-molecule ^{131}I-MIP-1095 demonstrated a superior therapeutic range in comparison to the antibody approach with PSA responses in 17 of 28 patients who were treated with a single cycle of mean 4.8 GBq.[91] However, the quantitatively high co-emission of high-energy photons arising from ^{131}I-MIP1095 in the whole-body remainder contributed relevantly to the red marrow dose (0.3 Gy/GBq) and it also requires extensive radiation protection efforts.[91] Unlike ^{131}I, ^{177}Lu has a better beta-to-gamma ratio that makes it preferable for clinical routine and reduces whole-body dose. Therefore, PSMA ligands carrying more universal chelates were developed. ^{177}Lu-DOTAGA-(I-y)fk(Sub-KuE) was administered to a larger patient series ($n = 56$).[92] High-absorbed tumor doses of median 3.3 Gy/GBq compared to normal organs of 0.8 Gy/GBq for kidneys or 1.3 Gy/GBq for salivary glands as well as a high rate of overall PSA responders without presence of severe acute toxicity were reported. The main limitation was a high variability of treatment activity (range: 3.6-8.7 GBq), which makes a comparison of these results to the findings of other studies difficult. PSMA-617 consists of the glu-urea motif and the DOTA chelator separated by a lipophilic-linker region, which favorable interacts with the hydrophobic accessory pocket that was found next to the catalytic domain of PSMA by Baiinka et al.[93] DOTA can be labeled with positron emitters like ^{44}Sc or ^{68}Ga, gamma emitters like ^{111}In, beta particle emitters like ^{90}Y or ^{177}Lu or alpha particle emitters like ^{213}Bi or ^{225}Ac. PSMA-617 was further refined in tumor-targeting with low nanomolar affinity in the range of $K_i = 0.37$ nM (NAALADase assay) and $K_i = 2.34$ nM (equilibrium dissociation constant on LNCaP) and highly efficient internalization with approximately 75% of the total cell–associated activity internalized after 3 hours of incubation in LNCaP. So far, PSMA-617 presents a superior combination of high receptor binding affinity, good internalization into PC cells, and low kidney uptake (Fig. 5).[40,94,95] The favorable dosimetry of the ligand PSMA-617 has been confirmed by different centers in Istanbul, Munich, Cologne, and Heidelberg.[85,96-98] In brief, red marrow dose is

approximately 0.03 Gy/GBq and kidney dose is 0.5-0.7 Gy/GBq, making salivary glands and lacrimal glands the dose-limiting organs with doses of 1.2-2.8 Gy/GBq. Tumor doses between 1.2 and 47.5 Gy/GBq (mean = 13.1 Gy/GBq) have been estimated by the Munich[97] or between 6 and 22 Gy/GBq by the Heidelberg[85] group. One of the earliest patients treated with two cycles of ^{177}Lu-PSMA-617 with a cumulative activity of 7.4 GBq presented a radiological complete response.[99] Succeeding case reports confirmatively presented patients with marked response to PSMA-RLT, even in challenging situations.[100,101] More structured data have been reported recently. In a case series of 24 patients receiving two cycles of ^{177}Lu-PSMA-617 with a mean dose of 6 GBq per cycle, the PSA response rate after the first cycle was approximately 80%. However, some patients presented with early relapse and in only 70% of the patients, the PSA response was sustained until 8-10 weeks after cycle-1.[102] The other case series reported 30 patients, receiving up to three cycles of ^{177}Lu-PSMA-617 therapy bimonthly with a typical treatment activity of 6 GBq.[85] Confirmatively, they found PSA response (any decline of PSA at week-8) in 70% of the patients after cycle-1. Again, the response was of limited duration in a portion of patients and only approximately 40% of the patients intended-to-treat presented with ongoing response until the restaging was performed in week-24, that is, 6 months and 3 cycles after initiation of treatment (Fig. 9). Beside few patients who died early after therapy by tumor progression, both centers only reported grade-1/2 hematologic toxicities and sporadically mild xerostomia and fatigue as side effects. According to the recommendations of the PC clinical trials' working-group criteria, both centers explicitly reported >50% PSA decline rate at week-8, which was found in good accordance with 41.6 %[102] and 43.3%[85] for 6 GBq ^{177}Lu-PSMA-617, respectively. In contrast, a smaller case series was treated with a higher activity of 7.4 GBq tagged to the ligand ^{177}Lu-PSMA-I&T and reported a >50% PSA response rate of 33% at week-8.[103] Regardless of the ^{177}Lu-labeled PSMA ligand used, all four authors reporting case series confirmatively reported well tolerability of PSMA-targeted RLT with no or only few grade-3/4 toxicities.[85,92,102,103] Nevertheless, all authors reported a portion of patients (20%-40%) that were refractory to treatment with ^{177}Lu-PSMA ligands despite a sufficient expression of PSMA in the preceding PSMA-PET/CT. Patients with diffuse-type red marrow infiltration that was considered a risk factor to develop higher hematotoxicity,[85] present another challenge. Replacing the beta particle emitter ^{177}Lu with an alpha particle emitter such as ^{213}Bi or ^{225}Ac is one promising option to overcome these limitations.[104] Preliminary results (Fig. 10) are more than promising.[105]

Conclusion and Future Perspectives on PSMA Imaging

As outlined above, there are several interesting application fields on how PSMA targeting in Nuclear Medicine can improve the clinical management of patients with PC. The already available experience provides a quite clear preview about the possibilities of these new techniques. However, some aspects need further validation with higher patient numbers or inside a prospective clinical trial.

Despite first being described as a quite prostate-specific target, PSMA has also been demonstrated in the neovasculature of several other kinds of cancer, such as kidney, bladder, lung,

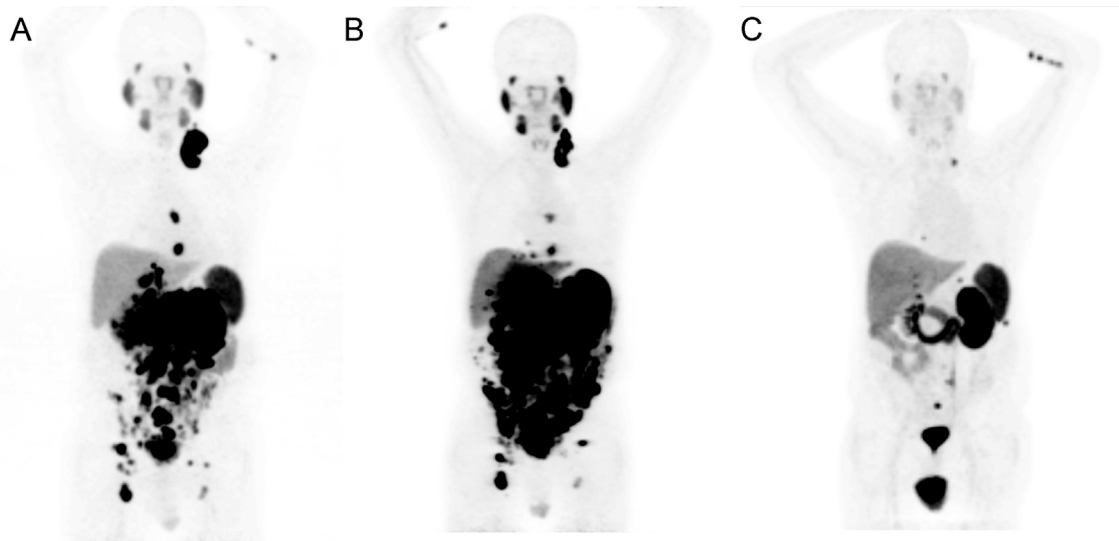

Figure 10 Maximum intensity projections (MIP) of ^{68}Ga-PSMA-11 PET/CTs. Initially, a patient with bulky lymph node metastases and infiltration of the liver presented with PSA of 294 ng/mL (A). After two cycles of 7.4 GBq ^{177}Lu-PSMA-617 therapies, imaging demonstrated progression of the pelvic and abdominal lesions and PSA increased to 419 ng/mL (B). After two additional cycles now conducted with 6.5 MBq ^{225}Ac-PSMA-617, the next restaging revealed favorable response and accordingly the PSA dropped to 3.5 ng/mL (C).

breast, colorectal, and pancreatic cancers, and in melanoma.[106] However, only few preliminary case reports but no systematic evaluation about the diagnostic accuracy of PSMA-PET/CT for non–prostate tumors is currently available, yet. Further studies are also needed to evaluate if the PSMA expressed in the neovasculature of these tumors internalizes after binding of a radioactive ligand, this would be an additional prerequisite for the therapeutic application of PSMA-RLT against other malignancies.

Recently, the first ^{68}Ge/^{68}Ga generator system was approved by the European Medicines Agency and a single-vial kit solution for radiolabeling ^{68}Ga-PSMA-11 at room temperature has been developed.[107] Thus, ^{68}Ga-PSMA-11 should become similarly practicable for clinical routine like using a conventional ^{99m}Tc tracer kit or like ^{18}F-PSMA ligands provided with a satellite concept.

References

1. Howlader N, Noone AM, Krapcho M, et al: SEER Cancer Statistics Review, 1975-2009 (Vintage 2009 Populations). Bethesda, MD: National Cancer Institute; 2012
2. Ferlay J, Steliarova-Foucher E, Lortet-Tieulent J, et al: Cancer incidence and mortality patterns in Europe: Estimates for 40 countries in 2012. Eur J Cancer 2013;49(6):1374-1403
3. Lozano R, Naghavi M, Foreman K, et al: Global and regional mortality from 235 causes of death for 20 age groups in 1990 and 2010: A systematic analysis for the Global Burden of Disease Study 2010. Lancet 2012;380(9859):2095-2128
4. Turkbey B, Brown AM, Sankineni S, et al: Multiparametric prostate magnetic resonance imaging in the evaluation of prostate cancer. CA Cancer J Clin 2015. [Epub ahead of print]
5. Bouchelouche K, Tagawa ST, Goldsmith SJ, et al: PET/CT imaging and radioimmunotherapy of prostate cancer. Semin Nucl Med 2011;41(1):29-44
6. Bjurlin MA, Rosenkrantz AB, Beltran LS, et al: Imaging and evaluation of patients with high-risk prostate cancer. Nat Rev Urol 2015;12(11):617-628
7. Jadvar H: Imaging evaluation of prostate cancer with ^{18}F-fluorodeoxyglucose PET/CT: Utility and limitations. Eur J Nucl Med Mol Imaging 2013;40:S5-S10 (suppl 1)
8. Schoder H, Herrmann K, Gonen M, et al: 2-[^{18}F]Fluoro-2-deoxyglucose positron emission tomography for the detection of disease in patients with prostate-specific antigen relapse after radical prostatectomy. Clin Cancer Res 2005;11:4761
9. Ren J, Yuan L, Wen G, et al: The value of anti-1-amino-3-^{18}F-fluorocyclobutane-1-carboxylic acid PET/CT in the diagnosis of recurrent prostate carcinoma: A meta-analysis. Acta Radiol 2016;57(4):487-493
10. Fanti S, Minozzi S, Castellucci P, et al: PET/CT with ^{11}C-choline for evaluation of prostate cancer patients with biochemical recurrence: Meta-analysis and critical review of available data. Eur J Nucl Med Mol Imaging 2016;43(1):55-69
11. Rajasekaran SA, Anilkumar G, Oshima E, et al: A novel cytoplasmic tail MXXXL motif mediates the internalization of prostate-specific membrane antigen. Mol Biol Cell 2003;14:4835-4845
12. Silver DA, Pellicer I, Fair WR, et al: Prostate-specific membrane antigen expression in normal and malignant human tissues. Clin Cancer Res 1997;3:81-85
13. Bostwick DG, Pacelli A, Blute M, et al: Prostate specific membrane antigen expression in prostatic intraepithelial neoplasia and adenocarcinoma: A study of 184 cases. Cancer 1998;82:2256-2261
14. Perner S, Hofer MD, Kim R, et al: Prostate-specific membrane antigen expression as a predictor of prostate cancer progression. Hum Pathol 2007;38:696-701
15. Chang SS: Overview of prostate-specific membrane antigen. Rev Urol 2004;6:S13-S18 (suppl 10)
16. Tykvart J, Navrátil V, Sedlák F, et al: Comparative analysis of monoclonal antibodies against prostate-specific membrane antigen (PSMA). Prostate 2014;74:1674-1690
17. Pandit-Taskar N, O'Donoghue O, Beylergil V, et al: ^{89}Zr J591 immuno-PET imaging in patients with advanced metastatic prostate cancer. Eur J Nucl Med Mol Imaging 2014;41:2093-2105
18. Kasten BB, Liu T, Nedrow-Byers JR, et al: Targeting prostate cancer cells with PSMA inhibitor-guided gold nanoparticles. Bioorg Med Chem Lett 2013;23:565-568
19. Mukherjee A, Darlington T, Holz R, et al: Development and screening of a series of antibody-conjugated and silica-coated iron oxide nanoparticles for targeting the prostate-specific membrane antigen. Chem Med Chem 2014;9:1356-1360
20. Chu TC, Marks JW, Lavery LA, et al: Aptamer: Toxin conjugates that specifically target prostate tumor cells. Cancer Res 2006;66:5989-5992
21. Baek SE, Lee KH, Park YS, et al: RNA aptamer-conjugated liposome as an efficient anticancer drug delivery vehicle targeting cancer cells in vivo. J Control Release 2014;196:234-242
22. Eder M, Eisenhut M, Babich J, et al: PSMA as a target for radiolabelled small molecules. Eur J Nucl Med Mol Imaging 2013;40:819-823
23. Maresca KP, Hillier SM, Lu G, et al: Small molecule inhibitors of PSMA incorporating technetium-99m for imaging prostate cancer: Effects of chelate design on pharmacokinetics. Inorg Chim Acta 2012;389:168-175
24. Banerjee SR, Foss CA, Castanares M, et al: Synthesis and evaluation of technetium-99m- and rhenium-labeled inhibitors of the prostate-specific membrane antigen (PSMA). J Med Chem 2008;51:4504-4517
25. Taneja SS: ProstaScint® scan: Contemporary use in clinical practice. Rev Urol 2004;6:19-28
26. Bander NH: Technology insight: Monoclonal antibody imaging of prostate cancer. Nat Clin Pract Urol 2006;3:216-225
27. Morris MJ, Divgi CR, Pandit-Taskar N, et al: Pilot trial of unlabeled and indium-111-labeled anti-prostate-specific membrane antigen antibody J591 for castrate metastatic prostate cancer. Clin Cancer Res 2005;11:7454-7461
28. Holland JP, Divilov V, Bander NH, et al: ^{89}Zr-DFO-J591 for immunoPET of prostate-specific membrane antigen expression in vivo. J Nucl Med 2010;51:1293-1300
29. Jackson PF, Slusher BS: Design of NAALADase inhibitors: A novel neuroprotective strategy. Curr Med Chem 2001;8:949-957
30. Kozikowski AP, Zhang J, Nan F, et al: Synthesis of urea-based inhibitors as active site probes of glutamate carboxypeptidase II: Efficacy as analgesic agents. J Med Chem 2004;47:1729-1738
31. Tiffany CW, Lapidus RG, Merion A, et al: Characterization of the enzymatic activity of PSM: Comparison with brain NAALADase. Prostate 1999;39:28-35
32. Mesters JR, Barinka C, Li W, et al: Structure of glutamate carboxypeptidase II, a drug target in neuronal damage and prostate cancer. EMBO J 2006;25:1375-1384
33. Maresca KP, Hillier SM, Femia FJ, et al: A series of halogenated heterodimeric inhibitors of prostate specific membrane antigen (PSMA) as radiolabeled probes for targeting prostate cancer. J Med Chem 2009;52:347-357
34. Hillier SM, Maresca KP, Femia FJ, et al: Preclinical evaluation of novel glutamate-urea-lysine analogues that target prostate-specific membrane antigen as molecular imaging pharmaceuticals for prostate cancer. Cancer Res 2009;69:6932-6940
35. Hillier SM, Maresca KP, Lu G, et al: ^{99m}Tc-labeled small-molecule inhibitors of prostate-specific membrane antigen for molecular imaging of prostate cancer. J Nucl Med 2013;54:1369-1376
36. Lu G, Maresca KP, Hillier SM, et al: Synthesis and SAR of ^{m}Tc/Re-labeled small molecule prostate specific membrane antigen inhibitors with novel polar chelates. Bioorg Med Chem Lett 2013;23:1557-1563
37. Eder M, Schafer M, Bauder-Wust U, et al: ^{68}Ga-complex lipophilicity and the targeting property of a urea-based PSMA inhibitor for PET imaging. Bioconjugate Chem 2012;23:688-697

38. Barrett JA, Coleman RE, Goldsmith SJ, et al: First-in-man evaluation of two high-affinity PSMA-avid small molecules for imaging prostate cancer. J Nucl Med 2013;54:380-387
39. Eder M, Neels O, Müller M, et al: Novel preclinical and radiopharmaceutical aspects of [^{68}Ga]Ga-PSMA-HBED-CC: A new PET tracer for imaging of prostate cancer. Pharmaceuticals (Basel) 2014;7:779-796
40. Benešová M, Schäfer M, Bauder-Wüst U, et al: Preclinical evaluation of a tailor-made DOTA-conjugated PSMA inhibitor with optimized linker moiety for imaging and endoradiotherapy of prostate cancer. J Nucl Med 2015;56:914-920
41. Chen Y, Pullambhatla M, Foss CA, et al: 2-(3-{1-Carboxy-5-[(6-[^{18}F] fluoro-pyridine-3-carbonyl)-amino]-pentyl}-ureido)-pentanedioic acid, [^{18}F]DCFPyL, a PSMA-based PET imaging agent for prostate cancer. Clin Cancer Res 2011;17:7645-7653
42. Lecornet E, Ahmed HU, Hu Y, et al: The accuracy of different biopsy strategies for the detection of clinically important prostate cancer: A computer simulation. J Urol 2012;188(3):974-980
43. Kelloff GJ, Choyke P, Coffey DS: Challenges in clinical prostate cancer: Role of imaging. AJR Am J Roentgenol 2009;192:1455
44. Rajinikanth A, Manoharan M, Soloway CT, et al: Trends in Gleason score: Concordance between biopsy and prostatectomy over 15 years. Urology 2008;72:177
45. Rahbar K, Weckesser M, Huss S, et al: Correlation of intraprostatic tumor extent with 68-Ga-PSMA distribution in patients with prostate cancer. J Nucl Med 2016;57(4):563-567
46. Giesel FL, Sterzing F, Schlemmer HP, et al: Intra-individual comparison of ^{68}Ga-PSMA11-PET/CT and multi-parametric MR for imaging of primary rostate cancer. Eur J Nucl Med Mol Imaging 2016. [Epub ahead of print]
47. Slawin Kevin Mark, Ellis William J, Tenke Peter, et al: A phase II study of ^{99m}Tc-trofolastat (MIP-1404) SPECT/CT to identify and localize prostate cancer in high-risk patients undergoing radical prostatectomy (RP) and extended pelvic lymph node dissection (EPLND) compared to histopathology: An interim analysis. J Clin Oncol 2014;32 [suppl 4; abstr 94]
48. D'Amico Anthony V, Whittington Richard, Malkowicz S Bruce, et al: Biochemical outcome after radical prostatectomy, external beam radiation therapy, or interstitial radiation therapy for clinically localized prostate cancer. J Am Med Assoc 1998;280(11):969-974
49. Roach M III, Marquez C, Yuo HS, et al: Predicting the risk of lymph node involvement using the pre-treatment prostate specific antigen and Gleason score in men with clinically localized prostate cancer. Int J Radiat Oncol Biol Phys 1994;28(1):33-37
50. Yu JB, Makarov DV, Gross C: A new formula for prostate cancer lymph node risk. Int J Radiat Oncol Biol Phys 2011;80(1):69-75
51. Sterzing F, Kratochwil C, Fiedler H, et al: ^{68}Ga-PSMA-11 PET/CT: A new technique with high potential for the radiotherapeutic management of prostate cancer patients. Eur J Nucl Med Mol Imaging 2016;43(1):34-41
52. Shakespeare TP: Effect of prostate-specific membrane antigen positron emission tomography on the decision-making of radiation oncologists. Radiat Oncol 2015;10:233
53. van Leeuwen PJ, Stricker P, Hruby G, et al: ^{68}Ga-Prostate-specific membrane antigen has a high detection rate of prostate cancer recurrence outside the prostatic fossa in patients being considered for salvage radiation treatment. BJU Int 2016;117(5):732-739
54. Heidenreich A, Ohlmann CH, Polyakov S: Anatomical extent of pelvic lymphadenectomy in patients undergoing radical prostatectomy. Eur Urol 2007;52(1):29-37
55. Weckermann D, Dorn R, Trefz M, et al: Sentinel lymph node dissection for prostate cancer: Experience with more than 1,000 patients. J Urol 2007;177(3):916-920
56. Van den Bergh L, Joniau S, Haustermans K, et al: Reliability of sentinel node procedure for lymph node staging in prostate cancer patients at high risk for lymph node involvement. Acta Oncol 2015;54(6):896-902
57. Hövels AM, Heesakkersb RA, Adang EM, et al: The diagnostic accuracy of CT and MRI in the staging of pelvic lymph nodes in patients withprostate cancer: A meta-analysis. Clin Radiol 2008;63:387-395
58. Giesel FL, Fiedler H, Stefanova M, et al: PSMA PET/CT with Glu-urea-Lys-(Ahx)-[Ga(HBED-CC)] versus 3D CT volumetric lymph node assessment in recurrent prostate cancer. Eur J Nucl Med Mol Imaging 2015;42(12):1794-1800
59. Hijazi S, Meller B, Leitsmann C, et al: See the unseen: Mesorectal lymph node metastases in prostate cancer. Prostate 2016;76(8):776-780
60. Herlemann A, Wenter V, Kretschmer A, et al: ^{68}Ga-PSMA positron emission tomography/computed tomography provides accurate staging of lymph node regions prior to lymph node dissection in patients with prostate cancer. Eur Urol 2016. [Epub ahead of print]
61. Hijazi S, Meller B, Leitsmann C, et al: Pelvic lymph node dissection for nodal oligometastatic prostate cancer detected by ^{68}Ga-PSMA-positron emission tomography/computerized tomography. Prostate 2015;75 (16):1934-1940
62. Schottelius M, Wirtz M, Eiber M, et al: [^{111}In]PSMA-I&T: Expanding the spectrum of PSMA-I&T applications towards SPECT and radioguided surgery. EJNMMI Res 2015;5(1):68
63. Afshar-Oromieh A, Avtzi E, Giesel FL, et al: The diagnostic value of PET/CT imaging with the ^{68}Ga-labelled PSMA ligand HBED-CC in the diagnosis of recurrent prostate cancer. Eur J Nucl Med Mol Imaging 2015;42(2):197-209
64. Eiber M, Maurer T, Souvatzoglou M, et al: Evaluation of hybrid Ga-PSMA ligand PET/CT in 248 patients with biochemical recurrence after radical prostatectomy. J Nucl Med 2015;56(5):668-674
65. Ceci F, Uprimny C, Nilica B, et al: ^{68}Ga-PSMA PET/CT for restaging recurrent prostate cancer: Which factors are associated with PET/CT detection rate? Eur J Nucl Med Mol Imaging 2015;42(8):1284-1294
66. Morigi JJ, Stricker PD, van Leeuwen PJ, et al: Prospective comparison of ^{18}F-fluoromethylcholine versus ^{68}Ga-PSMA PET/CT in prostate cancer patients who have rising PSA after curative treatment and are being considered for targeted therapy. J Nucl Med 2015;56(8):1185-1190
67. Afshar-Oromieh A, Zechmann CM, Malcher A, et al: Comparison of PET imaging with a ^{68}Ga-labelled PSMA ligand and ^{18}F-choline-based PET/CT for the diagnosis of recurrent prostate cancer. Eur J Nucl Med Mol Imaging 2014;41(1):11-20
68. Heidenreich A, Bastian PJ, Bellmunt J, et al: EAU guidelines on prostate cancer. Part II: Treatment of advanced, relapsing, and castration-resistant prostate cancer. Eur Urol 2014;65:467-479
69. Bluemel C, Krebs M, Polat B, et al: ^{68}Ga-PSMA-PET/CT in patients with biochemical prostate cancer recurrence and negative ^{18}F-choline-PET/CT. Clin Nucl Med 2016:11
70. Kähkönen E, Jambor I, Kemppainen J, et al: In vivo imaging of prostate cancer using [^{68}Ga]-labeled bombesin analog BAY86-7548. Clin Cancer Res 2013;19(19):5434-5443
71. Sah BR, Burger IA, Schibli R, et al: Dosimetry and first clinical evaluation of the new ^{18}F-radiolabeled bombesin analogue BAY 864367 in patients with prostate cancer. J Nucl Med 2015;56(3):372-378
72. Minamimoto R, Hancock S, Schneider B, et al: Pilot comparison of ^{68}Ga-RM2 PET and ^{68}Ga-PSMA PET in patients with biochemically recurrent prostate cancer. J Nucl Med 2016;57:557-562
73. Liolios C, Schäfer M, Haberkorn U, et al: Novel bispecific PSMA/GRPr targeting radioligands with optimized pharmacokinetics for improved PET imaging of prostate cancer. Bioconjug Chem 2016. [Epub ahead of print]
74. Even-Sapir E, Metser U, Mishani E, et al: The detection of bone metastases in patients with high-risk prostate cancer: ^{99m}Tc-MDP planar bone scintigraphy, single- and multi-field-of-view SPECT, ^{18}F-fluoride PET, and ^{18}F-fluoride PET/CT. J Nucl Med 2006;47(2):287-297
75. Dehdashti F, Picus J, Michalski JM, et al: Positron tomographic assessment of androgen receptors in prostatic carcinoma. Eur J Nucl Med Mol Imaging 2005;32(3):344-350
76. Olbert PJ, Hegele A, Kraeuter P, et al: Clinical significance of a prostate-specific antigen flare phenomenon in patients with hormone-refractory prostate cancer receiving docetaxel. Anticancer Drugs 2006;17:993-996
77. Kuroda K, Liu H, Kim S, et al: Docetaxel down-regulates the expression of androgen receptor and prostate-specific antigen but not prostate-specific membrane antigen in prostate cancer cell lines: Implications for PSA surrogacy. Prostate 2009;69(14):1579-1585
78. Nossa Kenneth R, Wolfe Steven A, Grimes Sidney R: Upregulation of prostate specific membrane antigen/folate hydrolase transcription by an enhancer. Gene 2002;285(1-2):247-256

79. Wright GL Jr., Grob BM, Haley C, et al: Upregulation of prostate-specific membrane antigen after androgen-deprivation therapy. Urology 1996;48:326-334
80. Liu T, Wu LY, Fulton MD, et al: Prolonged androgen deprivation leads to downregulation of androgen receptor and prostate-specific membrane antigen in prostate cancer cells. Int J Oncol 2012;41(6):2087-2092
81. Meller B, Bremmer F, Sahlmann CO, et al: Alterations in androgen deprivation enhanced prostate-specific membrane antigen (PSMA) expression in prostate cancer cells as a target for diagnostics and therapy. EJNMMI Res 2015;5(1):66
82. Murphy G, Ragde H, Kenny G, et al: Comparison of prostate specific membrane antigen, and prostate specific antigen levels in prostatic cancer patients. Anticancer Res 1995;15(4):1473-1479
83. Evans MJ, Smith-Jones PM, Wongvipat J, et al: Noninvasive measurement of androgen receptor signaling with a positron-emitting radiopharmaceutical that targets prostate-specific membrane antigen. Proc Natl Acad Sci U S A 2011;108(23):9578-9582
84. Uprimny C, Kroiss A, Nilica B, et al: ^{68}Ga-PSMA ligand PET versus ^{18}F-NaF PET: Evaluation of response to ^{223}Ra therapy in a prostate cancer patient. Eur J Nucl Med Mol Imaging 2015;42(2):362-363
85. Kratochwil C, Giesel FL, Stefanova M, et al: PSMA-targeted radionuclide therapy of metastatic castration-resistant prostate cancer with Lu-177 labeled PSMA-617. J Nucl Med 2016. [Epub ahead of print]
86. Crawford ED, Higano CS, Shore ND, et al: Treating patients with metastatic castration resistant prostate cancer: A comprehensive review of available therapies. J Urol 2015;194:1537-1547
87. van Soest RJ, van Royen ME, de Morrée ES, et al: Cross-resistance between taxanes and new hormonal agents abiraterone and enzalutamide may affect drug sequence choices in metastatic castration-resistant prostate cancer. Eur J Cancer 2013;49:3821-3830
88. Ma D, Hopf CE, Malewicz AD, et al: Potent antitumor activity of an auristatin-conjugated, fully human monoclonal antibody to prostate-specific membrane antigen. Clin Cancer Res 2006;12:2591-2596
89. Rose JN, Crook JM: The role of radiation therapy in the treatment of metastatic castrate-resistant prostate cancer. Ther Adv Urol 2015; 7:135-145
90. Vallabhajosula S, Nikolopoulou A, Jhanwar YS, et al: Radioimmunotherapy of metastatic prostate cancer with ^{177}Lu-DOTAhuJ591 anti prostate specific membrane antigen specific monoclonal antibody. Curr Radiopharm 2016;9(1):44-53
91. Zechmann CM A, Afshar-Oromieh A, Armor T, et al: Radiation dosimetry and first therapy results with a ^{124}I/^{131}I-labeled small molecule (MIP-1095) targeting PSMA for prostate cancer therapy. Eur J Nucl Med Mol Imaging 2014;41(7):1280-1292
92. Baum RP, Kulkarni HR, Schuchardt C, et al: Lutetium-177 PSMA radioligand therapy of metastatic castration-resistant prostate cancer: Safety and efficacy. J Nucl Med 2016. [Epub ahead of print]
93. Barinka C, Byun Y, Dusich CL, et al: Interactions between human glutamate carboxypeptidase II and urea-based inhibitors: Structural characterization. J Med Chem 2008;51:7737-7743
94. Gourni E, Canovas C, Goncalves V, et al: (R)-NODAGA-PSMA: A versatile precursor for radiometal labeling and nuclear imaging of PSMA-positive tumors. PLoS One 2015;10:e0145755
95. Benešová M, Bauder-Wüst U, Schäfer M, et al: Linker modification strategies to control the prostate-specific membrane antigen (PSMA)-targeting and pharmacokinetic properties of DOTA-conjugated PSMA inhibitors. J Med Chem 2016;59(5):1761-1775
96. Kabasakal L, AbuQbeitah M, Aygün A, et al: Pre-therapeutic dosimetry of normal organs and tissues of ^{177}Lu-PSMA-617 prostate-specific membrane antigen (PSMA) inhibitor in patients with castration-resistant prostate cancer. Eur J Nucl Med Mol Imaging 2015;42(13):1976-1983
97. Delker A, Fendler WP, Kratochwil C, et al: Dosimetry for ^{177}Lu-DKFZ-PSMA-617: A new radiopharmaceutical for the treatment of metastatic prostate cancer. Eur J Nucl Med Mol Imaging 2016;43(1):42-51
98. Hohberg M, Eschner W, Schmidt M, et al: Represent organs at risk for radionuclide therapy of prostate cancer with [^{177}Lu]DKFZ-PSMA-617. Mol Imaging Biol 2016;18
99. Kratochwil C, Giesel FL, Eder M, et al: [^{177}Lu]Lutetium-labelled PSMA ligand-induced remission in a patient with metastatic prostate cancer. Eur J Nucl Med Mol Imaging 2015;42(6):987-988
100. Soydal C, Ozkan E, Akyurek S, et al: Marked response to ^{177}Lu prostate-specific membrane antigen treatment in patient with metastatic prostate cancer. Clin Nucl Med 2016;41(2):159-160
101. Schlenkhoff CD, Gaertner F, Essler M, et al: Positive influence of ^{177}Lu PSMA-617 therapy on bone marrow depression caused by metastatic prostate cancer. Clin Nucl Med 2016;41
102. Ahmadzadehfar H, Eppard E, Kürpig S, et al: Therapeutic response and side effects of repeated radioligand therapy with ^{177}Lu-PSMA-DKFZ-617 of castrate-resistant metastatic prostate cancer. Oncotarget 2016. [Epub ahead of print]
103. Heck MM, Retz M,D, Alessandria C, et al: Systemic radioligand therapy with ^{177}Lu-PSMA-I&T in patients with metastatic castration-resistant prostate cancer. J Urol 2016. [Epub ahead of print]
104. Kratochwil C, Giesel FL, Bruchertseifer F, et al: Bi-DOTATOC receptor-targeted alpha-radionuclide therapy induces remission in neuroendocrine tumours refractory to beta radiation: A first-in-human experience. Eur J Nucl Med Mol Imaging 2014;41:2106-2119
105. Kratochwil C, Bruchertseifer F, Giesel FL, et al: Ac-225-PSMA617 PSMA-gerichtete Alpha-Strahler-Therapie des metastasierten Prostatakarzinoms. Nuklearmedizin 2016;54:A26-V68
106. Milowsky MI, Nanus DM, Kostakoglu L, et al: Vascular targeted therapy with anti-prostate-specific membrane antigen monoclonal antibody J591 in advanced solid tumors. J Clin Oncol 2007;25(5): 540-547
107. Ebenhan T, Vorster M, Marjanovic-Painter B, et al: Development of a single vial kit solution for radiolabeling of ^{68}Ga-DKFZ-PSMA-11 and its performance in prostate cancer patients. Molecules 2015;20(8): 14860-14878